



Protocol for the Examination of Specimens From Patients with Well-Differentiated Neuroendocrine Tumors (Carcinoid Tumors) of the Duodenum and Ampulla of Vater

Version: 2.0.0.1

Protocol Posting Date: June 2024

CAP Laboratory Accreditation Program Protocol Required Use Date: September 2024

The changes included in this current protocol version do not affect the prior accreditation date.

For accreditation purposes, this protocol should be used for the following procedures AND tumor types:

Procedure	Description
Resection	Includes specimens designated segmental duodenum resection, pancreaticoduodenectomy (Whipple resection)
Tumor Type	Description
Well-differentiated neuroendocrine tumor of the duodenum and the ampulla	

This protocol is NOT required for accreditation purposes for the following:

Procedure
Biopsy
Excisional biopsy (includes endoscopic resection, local resection, and ampullectomy)
Primary resection specimen with no residual cancer (e.g., following neoadjuvant therapy)
Recurrent tumor
Cytologic specimens

The following tumor types should NOT be reported using this protocol:

Tumor Type
Well-differentiated neuroendocrine tumors of the jejunum and ileum (consider the Jejunum and Ileum Neuroendocrine Tumor protocol)
Poorly differentiated neuroendocrine carcinoma including small cell and large cell neuroendocrine carcinoma (consider the Small Intestine protocol)
Other epithelial carcinomas including mixed neuroendocrine-non-neuroendocrine neoplasms (consider the Small Intestine protocol)
Lymphoma (consider the Precursor and Mature Lymphoid Malignancies protocol)
Gastrointestinal stromal tumor (GIST) (Consider the GIST protocol)
Non-GIST sarcoma (consider the Soft Tissue protocol)

Authors

Dhanpat Jain, MD*; William V. Chopp, MD*; Rondell P. Graham, MBBS*.

With guidance from the CAP Cancer and CAP Pathology Electronic Reporting Committees.

* Denotes primary author.

Accreditation Requirements

This protocol can be utilized for a variety of procedures and tumor types for clinical care purposes. For accreditation purposes, only the definitive primary cancer resection specimen is required to have the core and conditional data elements reported in a synoptic format.

- Core data elements are required in reports to adequately describe appropriate malignancies. For accreditation purposes, essential data elements must be reported in all instances, even if the response is “not applicable” or “cannot be determined.”
- Conditional data elements are only required to be reported if applicable as delineated in the protocol. For instance, the total number of lymph nodes examined must be reported, but only if nodes are present in the specimen.
- Optional data elements are identified with “+” and although not required for CAP accreditation purposes, may be considered for reporting as determined by local practice standards.

The use of this protocol is not required for recurrent tumors or for metastatic tumors that are resected at a different time than the primary tumor. Use of this protocol is also not required for pathology reviews performed at a second institution (i.e., secondary consultation, second opinion, or review of outside case at second institution).

Synoptic Reporting

All core and conditionally required data elements outlined on the surgical case summary from this cancer protocol must be displayed in synoptic report format. Synoptic format is defined as:

- Data element: followed by its answer (response), outline format without the paired Data element: Response format is NOT considered synoptic.
- The data element should be represented in the report as it is listed in the case summary. The response for any data element may be modified from those listed in the case summary, including “Cannot be determined” if appropriate.
- Each diagnostic parameter pair (Data element: Response) is listed on a separate line or in a tabular format to achieve visual separation. The following exceptions are allowed to be listed on one line:
 - Anatomic site or specimen, laterality, and procedure
 - Pathologic Stage Classification (pTNM) elements
 - Negative margins, as long as all negative margins are specifically enumerated where applicable
- The synoptic portion of the report can appear in the diagnosis section of the pathology report, at the end of the report or in a separate section, but all Data element: Responses must be listed together in one location

Organizations and pathologists may choose to list the required elements in any order, use additional methods in order to enhance or achieve visual separation, or add optional items within the synoptic report. The report may have required elements in a summary format elsewhere in the report IN ADDITION TO but not as replacement for the synoptic report i.e., all required elements must be in the synoptic portion of the report in the format defined above.

CAP
Approved

DuodAmp.NET_2.0.0.1.REL_CAPCP

Summary of Changes

v 2.0.0.1

- Histologic Type answer spelling correction

Reporting Template

Protocol Posting Date: June 2024

Select a single response unless otherwise indicated.

CASE SUMMARY: (DUODENUM AND AMPULLA NEUROENDOCRINE TUMOR)

Standard(s): AJCC-UICC 9

SPECIMEN (Notes [A](#),[B](#))

Procedure

- Ampullectomy
- Endoscopic or local resection
- Duodenum, segmental resection
- Pancreaticoduodenectomy (Whipple resection)
- Other (specify): _____
- Not specified

TUMOR

Tumor Site (Note [C](#)) (select all that apply)

- Duodenum: _____
- First portion
- Second portion
- Third portion
- Fourth portion
- Ampulla: _____
- Other (specify): _____
- Cannot be determined: _____

Histologic Type and Grade# (Notes [D](#),[E](#))

For poorly differentiated (high-grade) neuroendocrine carcinomas arising in the small intestine or ampulla, the checklists for carcinomas of those organ sites should be used.

- G1, well-differentiated neuroendocrine tumor
- G2, well-differentiated neuroendocrine tumor
- G3, well-differentiated neuroendocrine tumor
- GX, grade cannot be assessed
- Other (specify): _____
- Not applicable: _____

Histologic Grade Determination (Note [E](#))

Mitotic rate and / or Ki-67 labeling index is required to determine histologic grade

Mitotic Rate (required only when Ki-67 labeling index is not reported)#

Mitotic rate should be reported as number of mitoses per 2 mm², by evaluating at least 10 mm² in the most mitotically active part of the tumor (e.g., if using a microscope with a field diameter of 0.55 mm, count 42 high power fields (10 mm²) and divide the resulting number of mitoses by 5 to determine the number of mitoses per 2 mm² needed to assign tumor grade).

- Not applicable (Ki-67 labeling index is reported)
- Specify number of mitoses per 2 mm²: _____ mitoses per 2 mm²
- Less than 2 mitoses per 2 mm²

- 2 to 20 mitoses per 2 mm²
- Greater than 20 mitoses per 2 mm²
- Cannot be determined (explain): _____

Ki-67 Labeling Index (required only when mitotic rate is not reported)

- Not applicable (mitotic rate is reported)
- Specify Ki-67 percentage: _____ %
- Less than 3%
- 3% to 20%
- Greater than 20%
- Cannot be determined (explain): _____

+Histologic Subtype (Notes [C](#),[D](#))

- Somatostatinoma
- Gastrinoma
- Composite gangliocytoma / neuroma and neuroendocrine tumor (previously known as gangliocytic paraganglioma)
- Other (specify): _____

Tumor Size (Note [F](#))

Specify size of largest tumor if multiple tumors are present

- Greatest dimension in Centimeters (cm): _____ cm
- +Additional Dimension in Centimeters (cm): _____ x _____ cm**
- Cannot be determined (explain): _____

Tumor Focality

- Unifocal
- Multifocal

Number of Tumors

- Specify number: _____
- Other (specify): _____
- Cannot be determined: _____
- Cannot be determined

Tumor Extent (select all that apply)

- Duodenal Tumor
 - Invades mucosa
 - Invades submucosa
 - Invades muscularis propria
 - Invades pancreas
 - Invades peripancreatic adipose tissue
 - Invades visceral peritoneum (serosa)
 - Invades other organ(s) (specify): _____
 - Cannot be determined: _____
- Ampullary Tumor
 - Confined within sphincter of Oddi
 - Invades through sphincter into duodenal submucosa

- Invades through sphincter into duodenal muscularis propria
- Invades pancreas
- Invades peripancreatic adipose tissue
- Invades visceral peritoneum (serosa)
- Invades other organ(s) (specify): _____
- Cannot be determined: _____
- No evidence of primary tumor

Lymphatic and / or Vascular Invasion

- Not identified
- Present
- Cannot be determined: _____

+Perineural Invasion

- Not identified
- Present
- Cannot be determined: _____

+Tumor Comment: _____

MARGINS (Note [G](#))

Margin Status

- All margins negative for tumor

+Closest Margin(s) to Tumor (select all that apply)

- Proximal: _____
- Distal: _____
- Radial: _____
- Mesenteric: _____
- Uncinate (retroperitoneal / superior mesenteric artery): _____
- Bile duct: _____
- Pancreatic neck / parenchymal: _____
- Mucosal: _____
- Deep: _____
- Other (specify): _____
- Cannot be determined: _____

+Distance from Tumor to Closest Margin

Specify in Centimeters (cm)

- Exact distance in cm: _____ cm
- Greater than 1 cm

Specify in Millimeters (mm)

- Exact distance in mm: _____ mm
- Greater than 10 mm

Other

- Other (specify): _____
- Cannot be determined: _____

- Tumor present at margin

Margin(s) Involved by Tumor (select all that apply)

- Proximal: _____
- Distal: _____
- Radial: _____
- Mesenteric: _____
- Uncinate (retroperitoneal / superior mesenteric artery): _____
- Bile duct: _____
- Pancreatic neck / parenchymal: _____
- Mucosal: _____
- Deep: _____
- Other (specify): _____
- Cannot be determined: _____
- Other (specify): _____
- Cannot be determined (explain): _____
- Not applicable

+Margin Comment: _____

REGIONAL LYMPH NODES

Regional Lymph Node Status

- Not applicable (no regional lymph nodes submitted or found)
- Regional lymph nodes present
 - All regional lymph nodes negative for tumor
 - Tumor present in regional lymph node(s)

Number of Lymph Nodes with Tumor

- Exact number (specify): _____
- At least (specify): _____
- Other (specify): _____
- Cannot be determined (explain): _____
- Other (specify): _____
- Cannot be determined (explain): _____

Number of Lymph Nodes Examined

- Exact number (specify): _____
- At least (specify): _____
- Other (specify): _____
- Cannot be determined (explain): _____

+Regional Lymph Node Comment: _____

DISTANT METASTASIS

Distant Site(s) Involved, if applicable (select all that apply)

- Not applicable
- Liver: _____
- Lung: _____

- Ovary: _____
- Nonregional lymph node(s): _____
- Peritoneum: _____
- Bone: _____
- Other (specify): _____
- Cannot be determined: _____

pTNM CLASSIFICATION (AJCC Version 9) (Note [H](#))

Reporting of pT, pN, and (when applicable) pM categories is based on information available to the pathologist at the time the report is issued. As per the AJCC (Chapter 1, 8th Ed.) it is the managing physician's responsibility to establish the final pathologic stage based upon all pertinent information, including but potentially not limited to this pathology report.

Modified Classification (required only if applicable) (select all that apply)

- Not applicable
- y (post-neoadjuvant therapy)
- r (recurrence)

pT Category#

Multiple tumors should be designated as such (the largest tumor should be used to assign T category). Use T(#); e.g., pT3(4) N0 M0, OR use the m suffix, T(m); e.g., pT3(m) N0 M0.

- pT not assigned (cannot be determined based on available pathological information)
- pT1: Tumor invades the mucosa or submucosa only, and is less than or equal to 1 cm in greatest dimension (duodenal tumors); tumor is less than or equal to 1 cm in greatest dimension and confined within the sphincter of Oddi (ampullary tumors)
- pT2: Tumor invades the muscularis propria or is greater than 1 cm in greatest dimension (duodenal tumors); tumor invades through sphincter into duodenal submucosa or muscularis propria, or is greater than 1 cm in greatest dimension (ampullary tumors)
- pT3: Tumor invades the pancreas or peripancreatic adipose tissue
- pT4: Tumor invades the visceral peritoneum (serosa) or other organs

T Suffix (required only if applicable)

- Not applicable
- (m) multiple primary synchronous tumors in a single organ

pN Category

- pN not assigned (no nodes submitted or found)
- pN not assigned (cannot be determined based on available pathological information)
- pN0: No tumor involvement of regional lymph node(s)
- pN1: Tumor involvement of regional lymph node(s)

pM Category (required only if confirmed pathologically)

- Not applicable - pM cannot be determined from the submitted specimen(s)

pM1: Microscopic confirmation of distant metastasis

- pM1a: Microscopic confirmation of metastasis confined to liver
- pM1b: Microscopic confirmation of metastasis in at least one extrahepatic site (e.g., lung, ovary, nonregional lymph node, peritoneum, bone)
- pM1c: Microscopic confirmation of both hepatic and extrahepatic metastases

CAP
Approved

DuodAmp.NET_2.0.0.1.REL_CAPCP

___ pM1 (subcategory cannot be determined)

ADDITIONAL FINDINGS (Note [!\)](#))

+Additional Findings (select all that apply)

- None identified
- Endocrine cell hyperplasia
- Tumor necrosis
- Psammoma bodies
- Other (specify): _____

COMMENTS

Comment(s): _____

Explanatory Notes

A. Application and Tumor Location

This protocol applies to well-differentiated neuroendocrine tumors (carcinoid tumors) of the duodenum and the ampulla of Vater. Poorly differentiated neuroendocrine carcinomas (small cell and large cell neuroendocrine carcinomas) and tumors with mixed glandular/neuroendocrine differentiation are not included.^{1,2} Well-differentiated neuroendocrine tumors of the jejunum and ileum use a different CAP cancer protocol.³

Because of site-specific similarities in histology, immunohistochemistry, and histochemistry, neuroendocrine tumors of the digestive tract have traditionally been subdivided into those of foregut, midgut, and hindgut origin (Table 1). In general, the distribution pattern along the gastrointestinal (GI) tract parallels that of the progenitor cell type, and the anatomic site of origin of GI neuroendocrine tumors is an important predictor of clinical behavior.⁴

Table 1. Site of Origin of Gastrointestinal Neuroendocrine Tumors

	Foregut Tumors	Midgut Tumors	Hindgut Tumors
Site	Stomach, Proximal Duodenum	Jejunum, Ileum, Appendix, Proximal Colon	Distal Colon, Rectum
Immunohistochemistry			
Chromogranin A	86%-100% +	82%-92% +	40%-58% +
Synaptophysin	50% +	95%-100% +	94%-100% +
Serotonin	33% + ⁵	86% + ⁵	45%-83% + ^{5,6,7,8,9}
Other Immunohistochemical Markers	Rarely, + for pancreatic polypeptide, histamine, gastrin, vasoactive intestinal peptide (VIP), or adrenocorticotrophic hormone (ACTH)	Prostatic acid phosphatase + in 20%-40% ^{10,11}	Prostatic acid phosphatase + in 20%-82% ^{5,6,7,8,9,10,11}
Carcinoid syndrome	Rare	5%-39% ^{12,13}	Rare

References

- Burghart L, Chopp WV, Jain D. Examination of Specimens From Patients With Carcinoma of Small Intestine. 2021. Available at www.cap.org/cancerprotocols.
- Burghart L, Chopp WV, Jain D.. Protocol for the Examination of Specimens From Patients With Carcinoma of the Ampulla of Vater. 2021. Available at www.cap.org/cancerprotocols.
- Jain D, Chopp WV, Graham RP. Protocol for the Examination of Specimens From Patients With Neuroendocrine Tumors of the Jejunum and Ileum. 2023. Available at www.cap.org/cancerprotocols.
- Rorstad O. Prognostic indicators for carcinoid neuroendocrine tumors of the gastrointestinal tract. *J Surg Oncol*. 2005;89(3):151-160.
- Eckhauser FE, Argenta LC, Strodel WE, et al. Mesenteric angiopathy, intestinal gangrene, and midgut carcinoids. *Surgery*. 1981;90(4):720-728.
- Modlin IM, Lye KD, Kidd M. A 5-decade analysis of 13,715 carcinoid tumors. *Cancer*. 2003;97(4):934-959.

7. Graeme-Cook F. Neuroendocrine tumors of the GI tract and appendix. In: Odze RD, Goldblum JR, Crawford JM, eds. *Surgical Pathology of the GI Tract, Liver, Biliary Tract, and Pancreas*. Philadelphia, PA: Saunders; 2004: 483-504.
8. Anlauf M, Garbrecht N, Henopp T, et al. Sporadic versus hereditary gastrinomas of the duodenum and pancreas: distinct clinico-pathological and epidemiological features. *World J Gastroenterol*. 2006;12(34):5440-5446.
9. Eckhauser FE, Argenta LC, Strodel WE, et al. Mesenteric angiopathy, intestinal gangrene, and midgut carcinoids. *Surgery*. 1981;90(4):720-728.
10. Kimura N, Sasano N. Prostate-specific acid phosphatase in carcinoid tumors. *Virchows Arch A Pathol Anat Histopathol*. 1986;410(3):247-251.
11. Nash SV, Said JW. Gastroenteropancreatic neuroendocrine tumors: a histochemical and immunohistochemical study of epithelial (keratin proteins, carcinoembryonic antigen) and neuroendocrine (neuron-specific enolase, bombesin and chromogranin) markers in foregut, midgut, and hindgut tumors. *Am J Clin Pathol*. 1986;86(2):415-422.
12. Williams GT. Endocrine tumours of the gastrointestinal tract: selected topics. *Histopathology*. 2007;50(1):30-41.
13. Garbrecht N, Anlauf M, Schmitt A, et al. Somatostatin-producing neuroendocrine tumors of the duodenum and pancreas: incidence, types, biological behavior, association with inherited syndromes, and functional activity. *Endocr Rel Cancer*. 2008;15(1):229-241.

B. Procedure

Depending on tumor size, stage, location, and functional status, the surgical options range from endoscopic resection to pancreatoduodenectomy.¹ In general, duodenal tumors <1 cm are treated by endoscopic or local resection, whereas a lymphadenectomy is included for those >2 cm. The surgical approaches for tumors of 1 cm to 2 cm remain controversial. Small gastrinomas are sometimes excised locally through duodenotomy. Segmental resection with reconstruction can be performed for the tumors in the first, third, and fourth portions of the duodenum without the involvement of ampulla of Vater.

References

1. AJCC Version 9 Neuroendocrine Tumors of the Duodenum and Ampulla Cancer Staging System. Copyright 2023 American College of Surgeons.

C. Site-Specific Features

Duodenal neuroendocrine tumors are relatively uncommon, accounting for roughly 4% of GI neuroendocrine tumors.¹ Most duodenal and ampullary NETs are nonfunctional. The most common functional tumor is the gastrin-secreting neuroendocrine tumor, or gastrinoma, associated with Zollinger-Ellison syndrome in one-third of cases.² These gastrin-secreting tumors are often associated with multiple endocrine neoplasia type 1 (MEN1) syndrome, but sporadic tumors also occur.³ Duodenal somatostatin-producing tumors (somatostatinomas) are less common, accounting for about 1% of GI neuroendocrine tumors, and are seldom associated with the functional syndrome of mild diabetes mellitus, cholelithiasis, and steatorrhea. These tumors often have a pure glandular growth pattern with scattered psammoma bodies and may be confused with conventional adenocarcinomas.⁴ They arise almost exclusively in the ampulla or periampullary duodenum and are often associated with neurofibromatosis type 1.⁵

Duodenal neuroendocrine tumors can arise in the first, second, third, or fourth portion of the duodenum, but more than 95% of them are located in the first and second portion, with those in the second portion

predominating in the ampullary region.⁶ Tumors arising in the third or fourth portion may behave more like jejunal and ileal neuroendocrine tumors. Most duodenal neuroendocrine tumors are unifocal but can be multifocal, especially in MEN1 patients with duodenal gastrinoma. Metastatic risk is increased by tumor size >2 cm, involvement of the muscularis propria, and mitotic activity.⁷

References

1. Modlin IM, Lye KD, Kidd M. A 5-decade analysis of 13,715 carcinoid tumors. *Cancer*. 2003;97(4):934-959.
2. Graeme-Cook F. Neuroendocrine tumors of the GI tract and appendix. In: Odze RD, Goldblum JR, Crawford JM, eds. *Surgical Pathology of the GI Tract, Liver, Biliary Tract, and Pancreas*. Philadelphia, PA: Saunders; 2004: 483-504.
3. Anlauf M, Garbrecht N, Henopp T, et al. Sporadic versus hereditary gastrinomas of the duodenum and pancreas: distinct clinico-pathological and epidemiological features. *World J Gastroenterol*. 2006;12(34):5440-5446.
4. Williams GT. Endocrine tumours of the gastrointestinal tract: selected topics. *Histopathology*. 2007;50(1):30-41.
5. Garbrecht N, Anlauf M, Schmitt A, et al. Somatostatin-producing neuroendocrine tumors of the duodenum and pancreas: incidence, types, biological behavior, association with inherited syndromes, and functional activity. *Endocr Rel Cancer*. 2008;15(1):229-241.
6. WHO Classification of Tumours Editorial Board. *Digestive system tumours*. Lyon (France): International Agency for Research on Cancer; 2019. (WHO classification of tumours series, 5th ed.; vol. 1).
7. Rorstad O. Prognostic indicators for carcinoid neuroendocrine tumors of the gastrointestinal tract. *J Surg Oncol*. 2005;89(3):151-160.

D. Histologic Type

The World Health Organization (WHO) classifies neuroendocrine neoplasms as well-differentiated neuroendocrine tumors (either the primary tumor or metastasis) and poorly differentiated neuroendocrine carcinomas.^{1,2,3} Historically, well-differentiated neuroendocrine tumors have been referred to as “carcinoid tumors,” a term which may cause confusion because, clinically, a carcinoid tumor is a serotonin-producing tumor associated with functional manifestations of carcinoid syndrome. The use of the term “carcinoid” for neuroendocrine tumor reporting is therefore discouraged for these reasons.

Classification of neuroendocrine tumors is based upon size, functionality, site, and invasion. Functioning tumors are those associated with clinical manifestations of hormone production or secretion of measurable amounts of active hormone; immunohistochemical demonstration of hormone production is not equivalent to clinically apparent functionality. Most functional tumors arising in the duodenum and the ampulla of Vater are gastrinomas. While somatostatinomas in the pancreas are associated with the functional syndrome of mild diabetes mellitus, cholelithiasis, and steatorrhea, those arising in the duodenum and the ampulla are always nonfunctional.

Composite gangliocytoma/neuroma and neuroendocrine tumor (CoGNET), previously called Gangliocytic paraganglioma, is another rare and unique neuroendocrine tumor arising in the ampulla of Vater or periampullary duodenum with a distinctive histology composed of 3 components: S-100-positive spindle cells, ganglion cells, and paraganglioma.⁴ These tumors are typically benign, and unlikely to lead to death despite rare patients with nodal metastasis. The endocrine components of the tumor are evaluated

similarly to other NETs, and the tumors are staged using this protocol, although any staging data specific to these tumors are lacking.

Immunohistochemistry and other ancillary techniques are generally not required to diagnose well-differentiated neuroendocrine tumors. Specific markers that may be used to establish neuroendocrine differentiation include chromogranin A, synaptophysin, INSM1, and CD56.² Because of their relative sensitivity and specificity, chromogranin A and synaptophysin are recommended, although INSM1 is also emerging as a good marker for endocrine differentiation.^{5,6}

Immunohistochemistry for specific hormone products, such as gastrin and somatostatin, may be of interest in some cases. However, immunohistochemical demonstration of hormone production does not equate with the clinical functionality of the tumor.

References

1. Graeme-Cook F. Neuroendocrine tumors of the GI tract and appendix. In: Odze RD, Goldblum JR, Crawford JM, eds. *Surgical Pathology of the GI Tract, Liver, Biliary Tract, and Pancreas*. Philadelphia, PA: Saunders; 2004: 483-504.
2. Williams GT. Endocrine tumours of the gastrointestinal tract: selected topics. *Histopathology*. 2007;50(1):30-41.
3. WHO Classification of Tumours Editorial Board. *Digestive system tumours*. Lyon (France): International Agency for Research on Cancer; 2019. (WHO classification of tumours series, 5th ed.; vol. 1).
4. AJCC Version 9 Neuroendocrine Tumors of the Duodenum and Ampulla Cancer Staging System. Copyright 2023 American College of Surgeons.
5. Zhang Q, Huang J, He Y, Cao R, Shu J. Insulinoma-associated protein 1(INSM1) is a superior marker for the diagnosis of gastroenteropancreatic neuroendocrine neoplasms: a meta-analysis. *Endocrine*. 2021;74(1):61-71.
6. McHugh KE, Mukhopadhyay S, Doxtader EE, Lanigan C, Allende DS. INSM1 Is a Highly Specific Marker of Neuroendocrine Differentiation in Primary Neoplasms of the Gastrointestinal Tract, Appendix, and Pancreas. *Am J Clin Pathol*. 2020;153(6):811-20.

E. Histologic Grade

Cytologic atypia in well-differentiated neuroendocrine tumors has no impact on clinical behavior of these tumors.

The WHO classification¹ and others² use mitotic rate and/or Ki-67 index as 1 of the criteria for potential for aggressive behavior. The mitotic rate should be reported as number of mitoses per 2 mm², by evaluating at least 10 mm² in the most mitotically active part of the tumor. Only clearly identifiable mitotic figures should be counted; hyperchromatic, karyorrhectic, or apoptotic nuclei are excluded. Because of variations in field size, the number of high-power field (HPF) (at 40X magnification) for 10 mm² (thereby 2 mm²) must be determined for each microscope (Table 2). For example, if using a microscope with a field diameter of 0.55 mm, count 42 HPF and divide the resulting number of mitoses by 5 to determine the number of mitoses per 2 mm² needed to assign tumor grade.

Table 2. Number of HPF Required for 10 mm¹ Using Microscopes with Different Field Diameter

Field Diameter (mm)	Area (mm ²)	Number of HPF for 10 mm ²
0.40	0.125	80
0.41	0.132	75
0.42	0.139	70
0.43	0.145	69
0.44	0.152	65
0.45	0.159	63
0.46	0.166	60
0.47	0.173	58
0.48	0.181	55
0.49	0.189	53
0.50	0.196	50
0.51	0.204	49
0.52	0.212	47
0.53	0.221	45
0.54	0.229	44
0.55	0.238	42
0.56	0.246	41
0.57	0.255	39
0.58	0.264	38
0.59	0.273	37
0.60	0.283	35
0.61	0.292	34
0.62	0.302	33
0.63	0.312	32
0.64	0.322	31
0.65	0.332	30
0.66	0.342	29
0.67	0.353	28
0.68	0.363	28
0.69	0.374	28

Ki-67 index is reported as percent positive tumor cells in area of highest nuclear labeling (“hot spot”), although the precise method of assessment has not been standardized. A number of methods have been used to assess Ki-67 index, including automatic counting and “eyeballing.”^{3,4} Automated counting is not widely available and requires careful modification of the software to circumvent the inaccuracies.³ Eyeballing can be used for most tumors; however, for tumors with Ki-67 index close to grade cut-offs, it is recommended to perform the manual count on the print of camera-captured image of the hot spot. It has been recommended that a minimum of 500 tumor cells be counted to determine the Ki-67 index, and a notation is made if less cells are available. Grade assigned based on Ki-67 index is typically higher than that based on mitotic count, and the case is assigned to the higher of the 2 if both methods are performed.¹

It is important to note that there are a small group of well-differentiated neuroendocrine tumors with a Ki-67 index >20% and a mitotic rate usually <20 per 10 HPF. In WHO-2010, these tumors were considered as G3 poorly differentiated neuroendocrine carcinomas. However, they have typical morphology of well-differentiated tumors.

Previous studies (most on pancreatic neuroendocrine tumors) have demonstrated that these tumors have a worse prognosis than grade 2 (Ki-67=3-20% and mitosis <20/10 HPF) neuroendocrine tumors, but they are not as aggressive as poorly differentiated neuroendocrine carcinomas.⁵ In addition, these tumors do not have the genetic abnormalities seen in poorly differentiated neuroendocrine carcinomas.⁶ Furthermore, unlike poorly differentiated neuroendocrine carcinomas, they are less responsive to platinum-based chemotherapy.⁷ In the WHO-2022 Blue Book of Endocrine Tumors, WHO-2019 Blue Book of Digestive System Tumors, and AJCC 9th edition, those with typical morphology of well-differentiated tumors are classified as “well-differentiated neuroendocrine tumor” but as grade 3 (Table 3).^{1,8,9}

Table 3. Recommended Grading System for Well-Differentiated Gastroenteropancreatic Neuroendocrine Tumors

Grade	Mitotic Rate (per 2mm ²)	Ki-67 index (%)
Well-differentiated neuroendocrine tumor, G1	<2	<3
Well-differentiated neuroendocrine tumor, G2	2-20	3-20
Well-differentiated neuroendocrine tumor, G3	>20	>20

References

1. WHO Classification of Tumours Editorial Board. *Digestive system tumours*. Lyon (France): International Agency for Research on Cancer; 2019. (WHO classification of tumours series, 5th ed.; vol. 1).
2. Rindi G, Kloppel G, Alhman H, et al; and all other Frascati Consensus Conference participants; European Neuroendocrine Tumor Society (ENETS). TNM staging of foregut (neuro)endocrine tumors: a consensus proposal including a grading system. *Virchows Arch*. 2006;449(4):395-401.
3. Tang LH, Gonen M, Hedvat C, Modlin I, Klimstra DS. Objective quantification of the Ki67 proliferative index in neuroendocrine tumors of gastroenteropancreatic system: a comparison of digital image analysis with manual methods. *Am J Surg Pathol*. 2012;36(12):1761-1770.
4. Reid MD, Bagci P, Ohike N, et al. Calculation of the Ki67 index in pancreatic neuroendocrine tumors: a comparative analysis of four counting methodologies. *Mod Pathol*. 2016;29(1):93.
5. Shi C, Klimstra DS. Pancreatic neuroendocrine tumors: pathologic and molecular characteristics. *Semin Diagn Pathol*. 2014;31(6):498-511.
6. Yachida S, Vakiani E, White CM, et al. Small cell and large cell neuroendocrine carcinomas of the pancreas are genetically similar and distinct from well-differentiated pancreatic neuroendocrine tumors. *Am J Surg Pathol*. 2012;36(2):173-184.
7. Sorbye H, Strosberg J, Baudin E, Klimstra DS, Yao JC. Gastroenteropancreatic high-grade neuroendocrine carcinoma. *Cancer*. 2014;120(18):2814-2823.
8. WHO Classification of Tumours Editorial Board (2022) *WHO classification of endocrine and neuroendocrine tumours*. Lyon, France: IARC.
9. AJCC Version 9 Neuroendocrine Tumors of the Duodenum and Ampulla Cancer Staging System. Copyright 2023 American College of Surgeons.

F. Tumor Size

For neuroendocrine tumors in any part of the GI tract, size greater than 2.0 cm is associated with a higher risk of lymph node metastasis. For duodenal NETs, nodal metastases occur in 3%, 13%, and 40% of patients with tumors smaller than 1.0 cm, between 1 cm and 2 cm, and larger than 2 cm, respectively.¹ However, duodenal gastrinomas frequently have lymph node metastasis even if they are

smaller than 1 cm. In addition, ampullary neuroendocrine tumors may be more likely to metastasize at a smaller size.

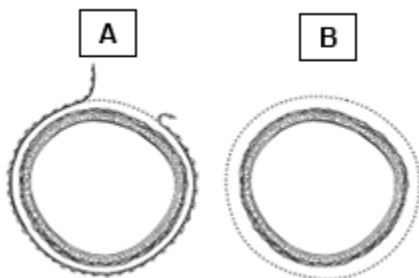
References

1. Kachare SD, Liner KR, Vohra NA, Zervos EE, Fitzgerald TL. A modified duodenal neuroendocrine tumor staging schema better defines the risk of lymph node metastasis and disease-free survival. *Am Surg.* 2014;80(8):821-826.

G. Margins

Circumferential (Radial or Mesenteric) Margin

In addition to addressing the proximal and distal margins, assessment of the circumferential (radial) margin is necessary for the duodenum either incompletely encased by peritoneum (Figure A) or unencased (Figure B). The circumferential margin represents the adventitial soft tissue margin closest to the deepest penetration of tumor and is created surgically by blunt or sharp dissection of the retroperitoneal or subperitoneal aspect, respectively. The distance between the tumor and circumferential (radial) margin should be reported. The circumferential (radial) margin is considered positive if the tumor is present at the inked nonperitonealized surface. This assessment includes tumor within a lymph node as well as direct tumor extension, but if circumferential (radial) margin positivity is based solely on intranodal tumor, this should be so stated.



- A. Circumferential (radial) margin (dotted line) in viscus incompletely encased by peritoneum.
B. Circumferential (radial) margin (dotted line) in viscus completely unencased by peritoneum.

Margins for Pancreaticoduodenectomy Specimens

The nonperitonealized surface of the uncinate process (uncinate margin) constitutes the inferior-posterior retroperitoneal margin of pancreaticoduodenectomy specimens. A perpendicular section through the closest approach of tumor to the margin should be taken. This margin has also been referred to as *retroperitoneal margin* and *superior mesenteric artery margin*. Complete en face sections through the pancreatic resection margin and the common bile duct margin should also be taken.

H. pTNM Classification

The TNM staging system for neuroendocrine tumors of the duodenum and ampulla of the American Joint Committee on Cancer (AJCC) and International Union Against Cancer (UICC) is recommended.¹

By AJCC/UICC convention, the designation “T” refers to a primary tumor that has not been previously treated. The symbol “p” refers to the pathologic classification of the TNM, as opposed to the clinical classification, and is based on gross and microscopic examination. pT entails a resection of the primary

tumor or biopsy adequate to evaluate the highest pT category, pN entails removal of nodes adequate to validate lymph node metastasis, and pM implies microscopic examination of distant lesions. Clinical classification (cTNM) is usually carried out by the referring physician before treatment during initial evaluation of the patient or when pathologic classification is not possible.

Pathologic staging is usually performed after surgical resection of the primary tumor. Pathologic staging depends on pathologic documentation of the anatomic extent of disease, whether or not the primary tumor has been completely removed. If a biopsied tumor is not resected for any reason (e.g., when technically unfeasible) and if the highest T and N categories or the M1 category of the tumor can be confirmed microscopically, the criteria for pathologic classification and staging have been satisfied without total removal of the primary cancer.

TNM Descriptors

For identification of special cases of TNM or pTNM classifications, the “m” suffix and “y,” “r,” and “a” prefixes are used. Although they do not affect the stage grouping, they indicate cases needing separate analysis.

The “m” suffix indicates the presence of multiple primary tumors in a single site and is recorded in parentheses: pT(m)NM.

The “y” prefix indicates those cases in which classification is performed during or following initial multimodality therapy (i.e., neoadjuvant chemotherapy, radiation therapy, or both chemotherapy and radiation therapy). The cTNM or pTNM category is identified by a “y” prefix. The ycTNM or ypTNM categorizes the extent of tumor actually present at the time of that examination. The “y” categorization is not an estimate of tumor prior to multimodality therapy (i.e., before initiation of neoadjuvant therapy).

The “r” prefix indicates a recurrent tumor when staged after a documented disease-free interval, and is identified by the “r” prefix: rTNM.

The “a” prefix designates the stage determined at autopsy: aTNM

T Category Considerations

Multiple tumors should be designated as such (and the largest tumor should be used to assign the T category):

- If the number of tumors is known, use T(#); e.g., pT3(4)N0M0
- If the number of tumors is unavailable or too numerous, use the suffix *m*—T(m)—e.g., pT3(m)N0M0

N Category Considerations

The regional lymph nodes for the duodenum and the ampulla of Vater vary with site. For duodenal tumors, the regional lymph nodes are duodenal, hepatic, pancreaticoduodenal, infrapyloric, gastroduodenal, pyloric, superior mesenteric, and pericholedochal nodes.

The regional nodes for the ampulla may be subdivided as follows:

Superior: Lymph nodes superior to head and body of pancreas

Inferior: Lymph nodes inferior to head and body of pancreas

Anterior: Anterior pancreaticoduodenal, pyloric, and proximal mesenteric lymph nodes

Posterior: Posterior pancreaticoduodenal, common bile duct or pericholedochal, and proximal mesenteric Nodes

M Category Considerations

The liver is the most common metastatic site for duodenal and ampullary neuroendocrine tumors. Metastases to extrahepatic sites, such as lung, ovary, peritoneum, and bone, are rare. Involvement of the celiac, para-aortic, and other nonregional lymph nodes is also considered M1 disease. In the AJCC Version 9, M is subcategorized into M1a (hepatic only), M1b (extrahepatic only), and M1c (both hepatic and extrahepatic).

References

1. AJCC Version 9 Neuroendocrine Tumors of the Duodenum and Ampulla Cancer Staging System. Copyright 2023 American College of Surgeons.

I. Additional Findings

Psammoma bodies are commonly found in duodenal neuroendocrine tumors, especially periampullary tumors¹ expressing somatostatin and associated with neurofibromatosis type 1.²

References

1. Burke AP, Sobin LH, Federspiel BH, Shekita KM, Helwig EB. Carcinoid tumors of the duodenum: a clinicopathologic study of 99 cases. *Arch Pathol Lab Med.* 1990;114(7):700-704.
2. Garbrecht N, Anlauf M, Schmitt A, et al. Somatostatin-producing neuroendocrine tumors of the duodenum and pancreas: incidence, types, biological behavior, association with inherited syndromes, and functional activity. *Endocr Rel Cancer.* 2008;15(1):229-241.